



# Anaesthetic Management Of A Patient With Adrenal Tumor Coming For Radical Nephrectomy.

Kaaviya. R<sup>1</sup>, Ashok Kumar DA<sup>2\*</sup>, Lakshmi. R<sup>3</sup>

<sup>1</sup>MBBS., MD Post Graduate Resident., Department of Anesthesiology, Saveetha Medical College and Hospital, Saveetha Institute of Medical and Technical Sciences, Saveetha University, Chennai, Tamilnadu, India.

<sup>2</sup>M.D. Anaesthesiology, MBA, Professor, Department of Anesthesiology, Saveetha Medical College and Hospital, Saveetha Institute of Medical and Technical Sciences, Saveetha University, Chennai, Tamilnadu, India.

<sup>3</sup>Head of the Department, Department of Anesthesiology, Saveetha Medical College and Hospital, Saveetha Institute of Medical and Technical Sciences, Saveetha University, Chennai, Tamilnadu, India.

\*Corresponding author - Ashok Kumar

M.D. Anaesthesiology, MBA, Professor, Department of Anesthesiology, Saveetha Medical College and Hospital, Saveetha Institute of Medical and Technical Sciences, Saveetha University, Chennai, Tamilnadu, India.

**Citation** Ashok Kumar et.al (2024) Anaesthetic Management Of A Patient With Adrenal Tumor Coming For Radical Nephrectomy, *Educational Administration: Theory and Practice*, 30(4), 364-374, Doi: 10.53555/kuey.v30i4.1479

## INTRODUCTION:

A renal cell carcinoma accounts for 2% of global cancer diagnoses and deaths, its incidence is increasing globally. The incidence of renal cell carcinoma is relatively low but many patients present late with advanced-stage disease and consequently, poorer prognosis. It has male predominance (M:F) and most common in sixth to eighth decades; peak incidence in sixth decade. Metastatic disease in 30% at diagnosis, and eventually in 50%(lung,liver,bone,distant LN, adrenal,brain, opposite kidney, soft tissue). Most sporadic renal cell carcinoma are unilateral and unifocal. The subtypes of Adenocarcinoma are clear cell(75-85%), chromophillic papillary (10-15%), chromophobe (5-10%), oncocytic(rare), sarcomatoid(1-6%; poor prognosis). Here we present the anesthetic management of a patient with adrenal mass and renal cell carcinoma coming for radical nephrectomy.

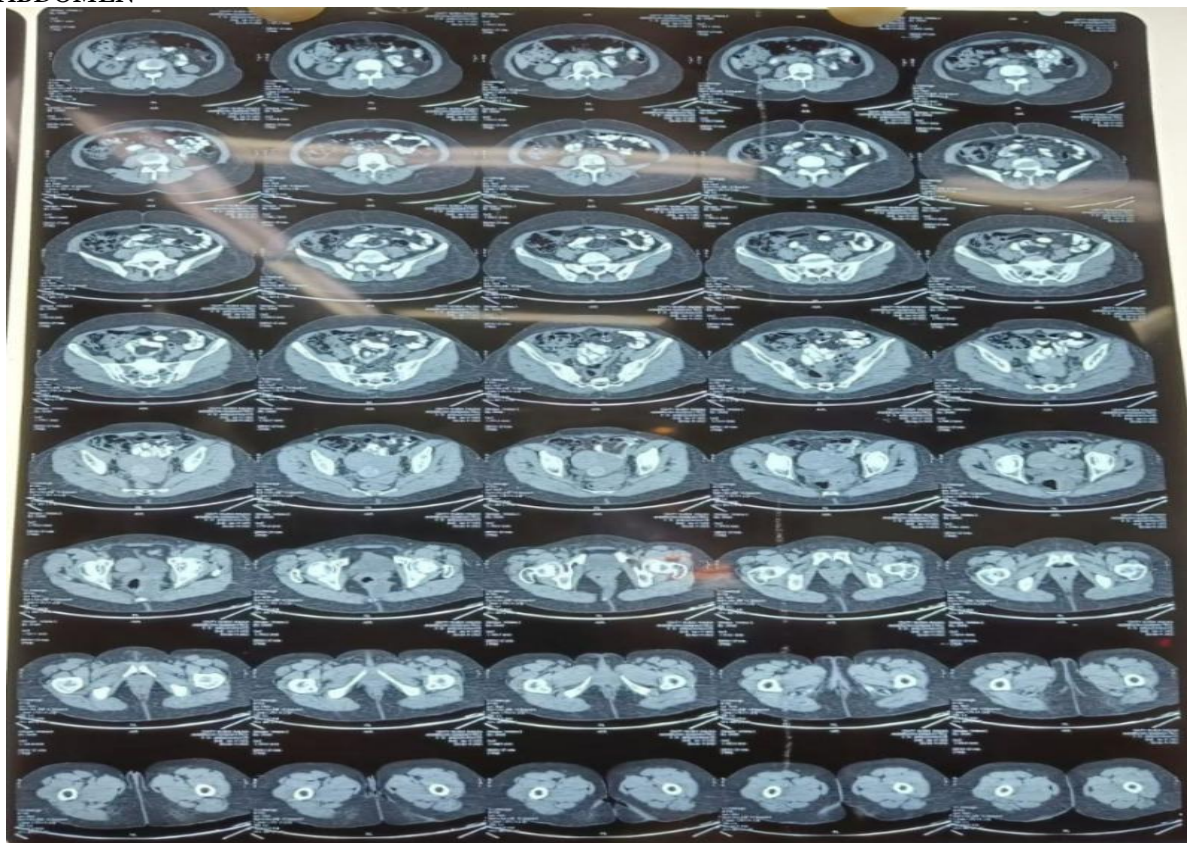
## CASE REPORT:

A 53 year old female got admitted with c/o abdominal pain on and off for 6 months duration. She also gave a history of palpitation and atypical chest pain for 8 months. She is a known case of systemic hypertension, bronchial asthma and chronic kidney disease. She gave history of previous surgery of appendectomy and LSCS 30 years back. On general examination the patient was awake, conscious, oriented, moderately built weighing 67 kg. She was afebrile with pulse- 78/ min, regular, good in volume.All peripheral pulses were felt. Her BP was130/90 mm hg measured in sitting position and respiratory rate was14 breaths/ min. The airway was assessed to be not a difficult airway.On systemic examination respiratory system showed chest movements and air entry were bilaterally equal, no adventitious sounds were present. On cardiovascular examination S1 and S2 heart sounds were heard. On central nervous system examination, patient was alert, conscious, well oriented to time, place and person. On per abdomen examination was soft and non tender.

The routine blood investigations were normal expect elevated renal function tests (Urea was 76 mg/dl, Creatinine was 1.7mg/dl and Uric acid 9.5mg/dl). Xray chest was normal, ECG showed no ST/T wave changes,Echo was done which showed ejection fraction was 60%,no regional wall motion abnormality,ultrasound thorax done which showed no significant abnormality but ultrasound abdomen showed cystitis, left renal simple cyst and right renal wall showed avascular heterogeneous hypoechoic complex mass. The ultrasound abdomen was followed by CT abdomen which revealed right adrenal mass measures 5\*4 cm, ?pheochromocytoma ?adrenal endothelial cyst.The hormonal assays showed serum metanephrine and 24 hrs urine VMA levels to be normal.Serum aldosterone was raised.Plasma levels of free metanephrines- 10.3 ng/dl(N:7.9-88.7).Plasma level of free nor metanephrine-**326ng/L**( N:20.1-135.40),3- methoxytyramine-4.95 ng/L(N:less than 18.40)Aldosterone -34.5(increased), Direct plasma renin-4.56ng/ml (increased),Aldosterone/renin ratio-7.56(increased).Serum aldosterone were elevated, Serum direct renin – elevated, Aldosterone renin ratio were elevated. Hence, it's a case of secondary hyperaldosteronism in view of elevated aldosterone renin ratio. During preoperative period she was started on alpha and beta blockers for fear of high blood pressure during introporative period due to phaeochromocytoma, handling of mass or aldosterone induced vasoconstriction causing malignant hypertension. Daily blood pressure chart was maintained. Raison criteria during immediate preop was checked- 12 lead ECG,any ectopics,orthostatic hypotension. In RCC, venous thrombus are common and hence IVC venogram is usually done, in our case IVC

venogram not done. Pet scan impression showing cystic lesion with thick septation arising from the right kidney is suspicious for renal primary tumor with suspicious retroperitoneal lymphnodal spread and with no obvious distant metastases. Various specialities opinion were obtained regarding cardiologist suggested patient can be assessed under moderate cardiac risk for surgery. Pulmonologist gave opinion of mild post-operative pulmonary complications for surgery and nebulization (Neb.budamate Q 12 hrly to be continued during perioperative period. Nephrologist suggested fluids upto 1.5-2 litres, daily RFT, S/E and to avoid nephrotoxic drugs and patient can be taken under moderate to high risk. Neurologist described the findings of incidental meningioma (11\*10 mm in cerebellum) and documented that not a contraindication for surgery. Ophthalmologist gave opinion in view of defective vision (HTN retinopathy)- 4years. She was worked up to be right supra renal mass, ? pheochromocytoma, ?RCC and planned for right side partial / radical nephrectomy. One month before surgery, she was started on T.phenoxybenzamine 10 mg BD PO and T.propanalol 40 mg BD. 10 days before surgery T.propanalol 40 mg BD was stopped. 1 week before surgery T.cilacar, T.met xl, T.amlong 5 mg od were started. Patient was posted for right radical nephrectomy under general anaesthesia with EA. Patient was taken up for surgery under ASA 3 with written informed consent for high risk, SICU and post ventilator support. Adequate blood and blood products were kept ready. Patient kept NPO by mouth overnight. Anesthesia plan was Epidural + General anaesthesia (for post-operative pain management). Preop antibiotic – inj.magnex forte 1.5 g IV. ICU bed and adequate blood and blood products were reserved. Patient was assessed under ASA classification 3.

#### CT ABDOMEN



#### INTRAOPERATIVE MANAGEMENT

Anaesthesia procedure was well explained to the patient during pre op visit. Operation theatre was prepared for surgery keeping in mind the anticipated and unanticipated problems. Drugs such as nitroglycerin, sodium nitroprusside, nor adrenaline, esmolol and phenylephrine were kept ready. One day before surgery T. Phenoxybenzamine 10 mg was stopped and all other hypertensives and nebulization were continued. 18 G IV line secured and intravenous crystalloid started. Basic monitors such as pulse oximeter, electrocardiogram, noninvasive blood pressure and temperature monitoring were done. Baseline vital parameters were recorded. Her blood pressure was 140/90 mm hg. Her heart rate, respiratory rate and saturation were 88/min, 12/min, 100% respectively.

Under aseptic precautions, epidural catheter was placed in L3- L4 intervertebral space using 22 G tuohy needle. Epidural space was confirmed with loss of resistance technique. After checking the patency of the catheter of size 18G, it was fixed at 12 cm in skin and test dose given.

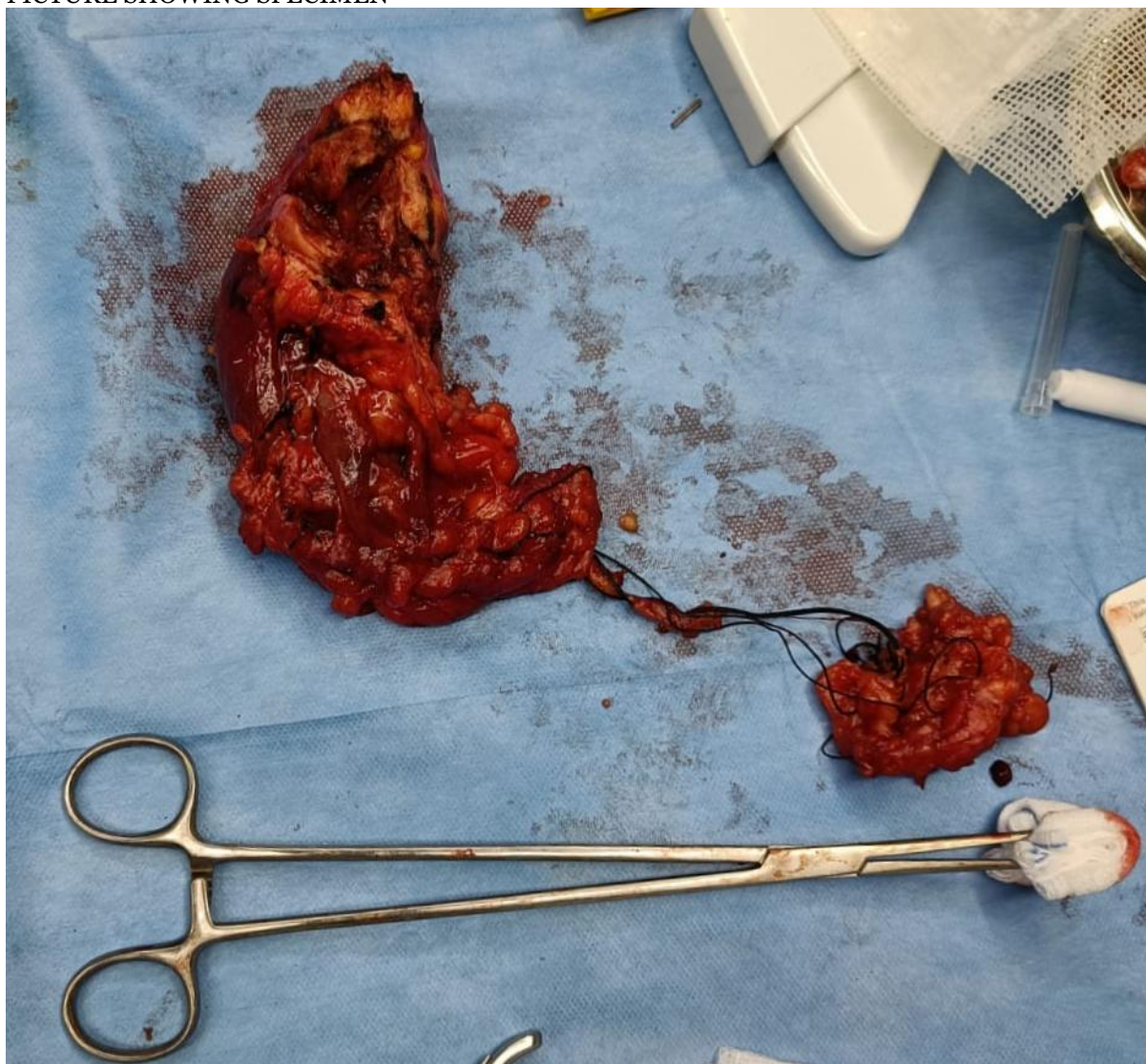
Patient was made supine and preoxygenated with 100% oxygen for 3 minutes with 4 number anatomical face mask. The patient was premedicated with injection midazolam 0.02 mg/kg, injection fentanyl 2 mcg/kg was given intravenously. Patient was induced with injection etomidate 0.3 mg/kg. Once induced able to ventilate



adequately was ensured, then injection cisatracurium 10 mg was given intravenously. Then patient was intubated with 7.5 mm cuffed endotracheal tube and fixed at 22cm at the right corner of the mouth. The right internal jugular vein was cannulated and central venous pressure line was secured. The right radial artery was cannulated and invasive arterial blood pressure monitoring was obtained. The patient was placed in right lateral position. The tumor was excised using a transperitoneal approach and subcostal incision. Post intubation patient was presented with blood pressure of 140/80 mm hg, heart rate of 82/min and saturation was 98% on 100% oxygen. Bilateral air entry were equal and adequate and no added sounds were found on auscultation of respiratory system. Anaesthesia was maintained with oxygen and nitrous oxide in the ratio 1:1. Isoflurane was used as inhalation agent to maintain surgical anesthesia and increments of 2 mg intravenous cisatracurium was given. Ventilation mode set as volume controlled ventilation, tidal volume of 500 ml, respiratory rate of 14/min, fraction of inspired oxygen is 50%, positive end expiratory pressure of 2cm of H<sub>2</sub>O. An hour after intubation epidural activated with injection bupivacaine 0.125 % at 4 ml/hr. Intraoperative period was uneventful except for blood loss which was duely replaced with two liters of crystalloids and two bags of packed red blood cells. The total blood loss was around 1450 ml and intraoperative urine output was 850 ml. At the end of the surgery, subcostal transverse abdominis plane block and right rectus sheath block was given. Total volume of drug given for block was around 20 ml of 0.5% ropivacaine. Patient was reversed with slow iv of 5 mg myoprolate and extubated on the table. Fentanyl patch 25 mcg/ hr placed was placed on the upper chest. Patient was then shifted to surgical intensive care unit.

Arterial blood gas analysis was done 15 minutes after extubation which was in normal range. Suggestion made for repeat complete blood count, renal function test, Serum electrolytes at 6 pm on the day of surgery. Capillary blood glucose monitoring done intraoperatively was normal and suggested Q6<sup>th</sup> hourly capillary blood glucose for the first two postoperative day.

#### PICTURE SHOWING SPECIMEN



#### POSTOPERATIVE PERIOD

Patient was in surgical intensive care unit for 3 days. Postoperative vitals and urine output were normal. For pain relief, epidural infusion of 0.125% bupivacaine at 6 ml/hr was used for first 48 hours. Fentanyl patch was removed 2 days after surgery.

During postop period, she was normotensive, euglycemic, no electrolyte imbalance and had adequate pain relief. Nebulisation was continued in post operative period and respiratory system on auscultation was clear. Injection hydrocortisone 100 mg/day was given in the surgical intensive care unit. She was ambulated on day 2 by surgeons and shifted to ward on postoperative day 3. She was discharged after 3 weeks from ward with follow up.

#### PICTURE SHOWING POSTOPERATIVE ABG

Blood Gas Values			
↓ pH	7.257		[ 7.350 - 7.450 ]
pCO <sub>2</sub>	37.5	mmHg	[ 32.0 - 48.0 ]
↑ pO <sub>2</sub>	173	mmHg	[ 83.0 - 110 ]
Temperature Corrected Values			
pH(T)	7.257		
pCO <sub>2</sub> (T)	37.5	mmHg	
? pO <sub>2</sub>	173	mmHg	
Electrolyte Values			
cNa <sup>+</sup>	141	mmol/L	[ 135 - 146 ]
cK <sup>+</sup>	4.1	mmol/L	[ 3.5 - 4.5 ]
cCa <sup>2+</sup>	1.25	mmol/L	[ 1.15 - 1.29 ]
↑ cCl <sup>-</sup>	121	mmol/L	[ 90 - 110 ]
Metabolite Values			
↑ cLac	2.5	mmol/L	[ 0.6 - 1.6 ]
Oximetry Values			
ctHb	9.7	g/dL	
sO <sub>2</sub>	97.7	%	
FO <sub>2</sub> Hb	96.6	%	
FHHb	2.3	%	
FCOHb	0.3	%	
FMetHb	0.8	%	
Acid Base Status			
cHCO <sub>3</sub> <sup>-</sup> (P) <sub>C</sub>	16.1	mmol/L	
ABE <sub>C</sub>	-9.8	mmol/L	
SBE <sub>C</sub>	-9.6	mmol/L	
cBase(B,ox) <sub>C</sub>	-9.9	mmol/L	
cBase(Ecf,ox) <sub>C</sub>	-9.7	mmol/L	
ctCO <sub>2</sub> (B) <sub>C</sub>	34.7	Vol%	
Calculated Values			
Anion Gap <sub>C</sub>	4.5	mmol/L	
Hct <sub>C</sub>	30.1	%	
pO <sub>2</sub> (A) <sub>E</sub>	669.2	mmHg	
? pO <sub>2</sub> (a/A) <sub>E</sub>	25.8	%	
? pO <sub>2</sub> (A-a) <sub>E</sub>	496.7	mmHg	
Baro <sub>E</sub>	754	mmHg	

## RESULTS

The adrenal tumour usually found incidentally during CT scan, needs to be assessed adequately for hormonal, metabolic dearrangements and should be corrected. The perioperative, intraoperative hypertension is common and should be optimised before surgery. These are the important factors to be considered during anaesthetic management of adrenal gland removal.

## REFERENCES:

- Kumamoto T, Nishi M. [Anesthetic management of a patient with renal cell carcinoma extending into the right atrium]. *Masui*. 2010 Apr;59(4):514-8. Japanese. PMID: 20420149.
- Fiekabo, H., & Victor, A. (2023). Anaesthetic Considerations in Managing Renal cell Carcinoma in a Resource-Poor Setting. *International Journal of Innovative Research in Medical Science*, 8(02), 44–4
- Lee HJ, Bae J, Kwon Y, Jang HS, Yoo S, Jeong CW, Kim JT, Kim WH. General Anesthetic Agents and Renal Function after Nephrectomy. *J Clin Med*. 2019 Sep 24;8(10):1530. doi: 10.3390/jcm8101530. PMID: 31554223; PMCID: PMC6832234.
- Poliac, L.; Chidiac, G.; Pretto, E.. Anesthetic management of renal cell carcinoma with supradiaphragmatic tumor thrombus extension, without the use of cardiopulmonary bypass: A-159. *European Journal of Anaesthesiology* 22():p 44, May 2005.
- M. Amendolara, C. Barbarino, D. Bucca et al., "Giant and bilateral adrenal myelolipoma," *Il Giornale di Chirurgia*, vol. 29, no. 3, pp. 85–88, 2008. View at: [Google Scholar](#)